

Isolated Myeloid Sarcoma In a Testis: A Case Report

Shahneela Manzoor,^{1*} Mazhar Iqbal,¹ Syed Muhammad Shafqatullah¹

ABSTRACT

A testicular myeloid sarcoma is uncommon tumor. We report a 20 years old patient who presented with right testicular swelling along with an abdominal mass. A provisional diagnosis of seminoma with para-aortic lymphadenopathy was made. Right Inguinal orchidectomy was done and histopathological report showed very rare tumor; the myeloid sarcoma.

Key words Myeloid testicular sarcoma, Acute myeloid leukemia, Testicular tumor.

INTRODUCTION:

Myeloid sarcoma is a rare condition that presents as an extramedullary tumor of immature granulocytic cells. It is associated mostly with acute myeloid leukemia (AML) although in some rare cases it may present in non-leukemia patients. Myeloid sarcoma may occur at any site of the body, more frequently in lymph nodes, skin, soft tissues, bone, peritoneum, and the gastrointestinal tract.^{1,2}

Myeloid sarcoma manifesting as a mass in the testis is uncommon. It usually occurs as a manifestation of bone marrow-based disease, usually AML, and less commonly with myelodysplastic or myeloproliferative disorders. Isolated myeloid sarcoma is a rare entity with an incidence of two cases per million adults, and its incidence is reported as 2.5-9% in patients with AML and less than 1% without bone marrow involvement.³ We report a case of primary testicular extramedullary myeloid tumor without preexisting or concomitant diagnosis of leukemia.

CASE REPORT:

A 20-years old male presented with right testicular swelling for two months and abdominal mass for one month. General physical examination was unremarkable. On inguinoscrotal examination right testis was enlarged, about 4x4 cm in size, non-tender, smooth surface, firm in consistency and testicular sensation was lost. On abdominal examination there was a mass palpable in upper mid

abdomen. Mass had nodular surface with ill-defined margins, and fixed. It extended from epigastrium to right hypochondrium. It was hard in consistency and upper limit was not reachable. Other lymph nodes were not enlarged.

Ultrasound of abdomen and scrotum showed enlarged testis with increased vascularity and distorted structures with the suspicion of testicular tumor. Abdominal ultrasound showed enlarged paraaortic lymph nodes. CT scan chest, abdomen and pelvis was done which showed ill-defined poorly enhancing homogenous soft tissue density mass 5x6 cm in size, occupying retroperitoneum within aorto-caval sulcus involving third part of the duodenum resulting in dilatation of stomach. It was also encasing the inferior vena cava and partially encasing the aorta. It was in close proximity to pancreas with blurring of fat planes. Complete picture of blood showed normal level of hemoglobin, leukocyte count and platelets. Tumor markers like serum alpha fetoprotein, beta-HCG and LDH were within normal limits.

Patient was admitted and decision of exploratory laparotomy was made as patient developed repeated vomiting to bypass duodenum which was obstructed by the mass and consent of right orchidectomy was also taken. At operation a huge mass obstructing the 2nd and 3rd parts of duodenum found. Gastrojejunostomy was done. Right orchidectomy along with spermatic cord were removed through inguinal approach. Specimen was sent for histopathology which showed sheets of large cells infiltrating the interstitium without obvious destruction of seminiferous tubules. Tumor involved base of spermatic cord. Cord resection margins were tumor free. Immunohistochemistry showed positive CD34, Myeloperoxidase (MPO), CD 117, LCA, CD 99 markers. Ki67 80% proliferation was index.

¹. Department of Surgery, JPMC, Karachi.

Correspondence:

Dr. Shahneela Manzoor ^{1*}
Department General Surgery Ward-2
Jinnah Postgraduate Medical Center (JPMC)
Karachi
Email: a.shani@live.com

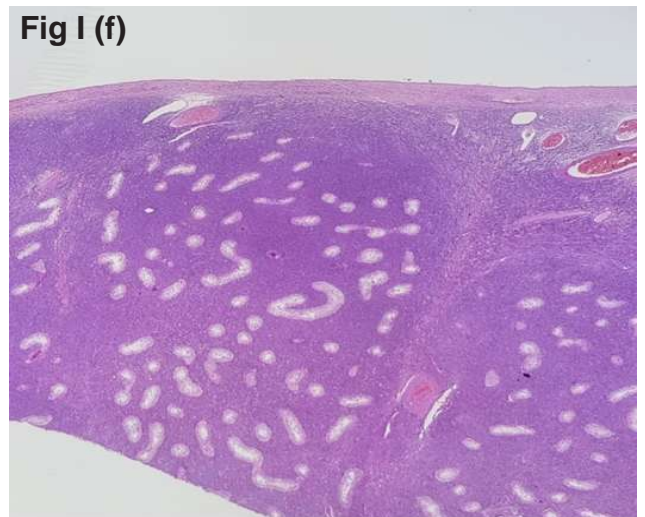
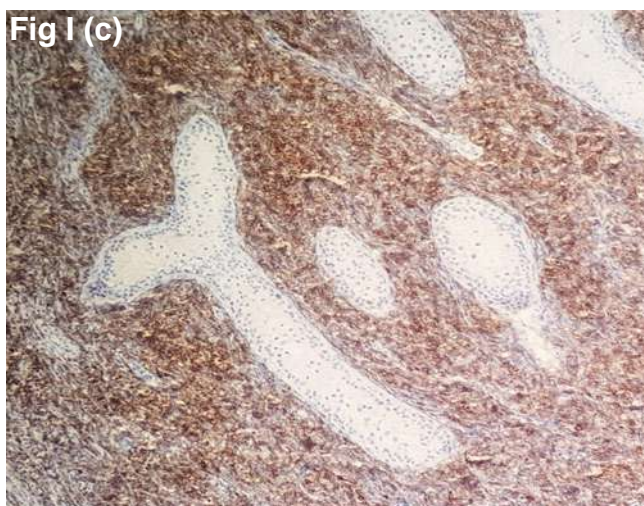
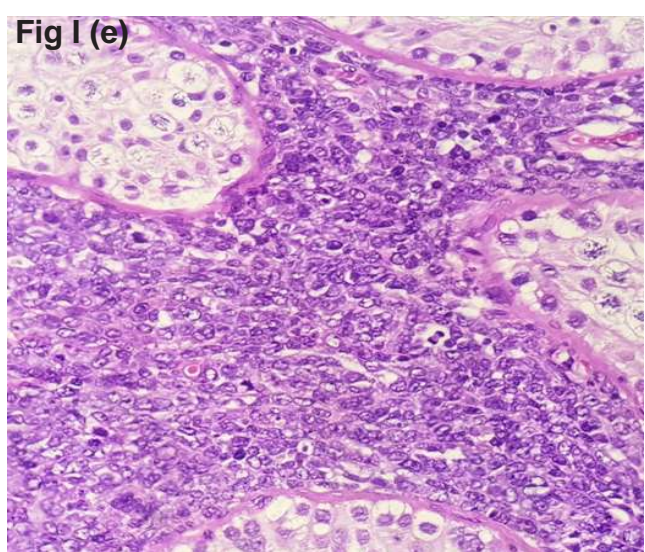
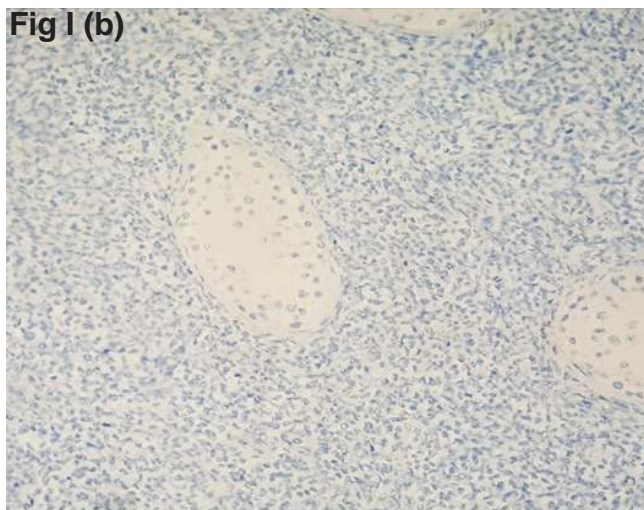
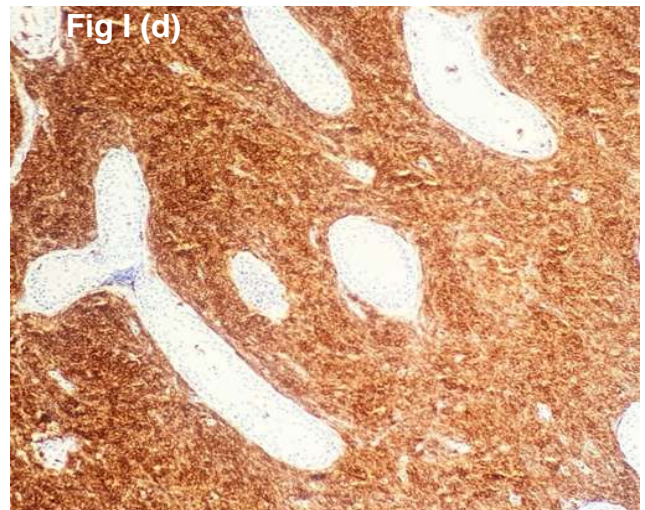
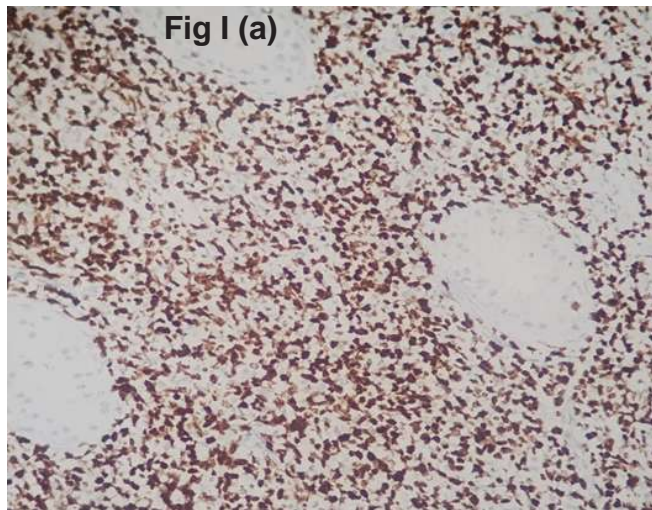


Fig-I: (a-f) Histopathology of the testicular tumor.

PAX-5 was weak positive. The diagnosis of testicular myeloid sarcoma was finally made (Fig I). Postoperatively vomiting was relieved. Patient started orally and send to oncology department for further treatment and chemoradiation.

DISCUSSION:

Testicular myeloid sarcoma is a rare primary tumor of testis. Our patient developed recurrent vomiting while he was being investigated. CT scan confirmed duodenal obstruction thus laparotomy was planned as a palliative gastrojejunostomy to relieve the

obstruction. Initial diagnosis was seminoma based upon clinical features and investigations. The misdiagnosis rate at initial presentation is reportedly high, with 47% of all myeloid sarcoma cases being suspected as malignant lymphoma.² Immunohistochemistry is the most useful histopathological adjunct to make final diagnosis.

Further investigations in cases of myeloid sarcoma include the cell type by bone marrow aspiration cytology, tumor markers including MPO, CD43, CD45, CD68, and others. A search for distant metastases by PET-CT is also advised. Treatment for myeloid sarcoma requires chemotherapy as done for leukemia.^{3,4} In our patient immunohistochemistry helped in making diagnosis. Local treatment options include radiation therapy, surgery, or both. Although surgery does not play an important role in patients with symptomatic myeloid sarcoma, resection or debulking can be considered before starting chemotherapy.^{2,4,5} Primary extra-medullary myeloid tumor of testis without pre-existing or concomitant diagnosis of leukemia is a very rare entity with poor prognosis.^{6,7}

REFERENCES:

1. Wang W, He HS, Chen XW, Zhang CH. Primary bronchial myeloid sarcoma mimicking bronchogenic carcinoma: a case report. *BMC Pulm Med.* 2019;19:204. DOI <https://doi.org/10.1186/s12890-019-0975-7>.
2. Almond LM, Charalampakis M, Ford SJ, Gourevitch D, Desai A. Myeloid sarcoma: presentation, diagnosis, and treatment. *Clin Lymphoma, Myeloma Leuk.* 2017;17:263-7. <https://doi.org/10.1016/j.clml.2017.02.027>.
3. Shahin OA, Ravandi F. Myeloid sarcoma. *Curr Opin Hematol.* 2020;27:88-94. doi:10.1097/MOH.0000000000000571
4. Magdy M, Abdel Karim N, Eldessouki I, Gaber O, Rahouma M, Ghareeb M. Myeloid sarcoma. *Oncol Res Treat.* 2019;42:219-24. <https://doi.org/10.1159/000497210>
5. Bakst RL, Tallman MS, Douer D, Yahalom J. How I treat extramedullary acute myeloid leukemia. *Blood.* 2011;118:3785-93. <https://doi.org/10.1182/blood-2011-04-347229>.
6. Valbuena JR, Admirand JH, Lin P, Medeiros LJ. Myeloid sarcoma involving the testis. *Am J Clin Pathol.* 2005;124: 445-52. DOI: 10.1309/NXLCJ1B16YDFQWND
7. Singh A, Kumar P, Chandrashekhara SH, Kumar A. Unravelling choroma: review of imaging findings. *Br J Radiol.* 2017;90(1075):20160710. doi: 10.1259/bjr.20160710

Received for publication: 26-08-2022

Accepted after revision: 30-09-2022

Author's Contributions:

Shahneela Manzoor: Manuscript writing

Mazhar Iqbal: Manuscript writing

Syed Muhammad Shafqatullah: Manuscript writing

All authors approved final version of the manuscript.

Ethical statement: Institution review board permission was obtained prior to the study and informed consent taken. Permission of the patient was taken to report this case for educational purpose maintaining the confidentiality.

Competing interest:

The authors declare that they have no competing interest.

Source of Funding: None

How to cite this article:

Manzoor S, Iqbal M, Shafqatullah SM. Isolated myeloid sarcoma in a testis: a case report. *J Surg Pakistan.* 2022; 27 (3):106-8. Doi:10.21699/jsp.27.3.7.

This is an open access article distributed in accordance with the Creative Commons Attribution (CC BY 4.0) license: <https://creativecommons.org/licenses/by/4.0/> which permits any use, Share — copy and redistribute the material in any medium or format, Adapt — remix, transform, and build upon the material for any purpose, as long as the authors and the original source are properly cited. © The Author(s) 2022