

# Intussusception After Two Decades of Gastrojejunostomy With Gastric Outlet Obstruction

Farhan Ahmed Majeed,<sup>1</sup> Hassan Shabbir,<sup>1\*</sup> Umar Bashir,<sup>1</sup> Ahmad Raza,<sup>1</sup>  
Nabeela Farhan,<sup>1</sup> Adil Qayyum<sup>1</sup>

## ABSTRACT

*Intussusception occurring through a retrograde jejuno gastric fashion is one the rare causes of gastric outlet obstruction. Our case, a 55 year old patient, presented with epigastric pain, projectile vomiting and hematemesis following meals and fever. Ultrasound revealed intussusception at the splenic flexure while endoscopy showed a bosselated mass in the area of the body of the stomach with intact mucosa and visible peristalsis in mass. CT scan of the abdomen revealed a whirlpool sign in the area of the splenic flexure. Patient had abdominal surgery 20 year back however, procedure detail were unknown. Exploration revealed the gastrojejunostomy intussusception. Reduction and stitching of the small gut to the mesentery was done to avoid recurrence. Postoperative recovery was uneventful.*

*Key words* Retrograde intussusception, Gastric surgery, Gastrojejunostomy.

## INTRODUCTION:

Jejunogastric intussusception, is uncommon that occurs after a previous gastric surgery like gastrojejunostomy and Billroth II gastrectomy.<sup>1</sup> Epidemiological studies showed only 300 cases of jejuno gastric intussusception that occurred after gastric surgery, an incidence of 0.1%.<sup>2</sup> This paper intends to report a case of retrograde jejuno gastric intussusception in a patient who had undergone gastrojejunostomy and presented with acute gastric obstruction that manifested as pain in the epigastric region and recurrent projectile vomiting with hematemesis especially after meals.

## CASE REPORT:

A 55-years old male patient presented with the complaints of pain in the epigastric region radiating to the back, recurrent projectile vomiting and hematemesis especially after meals for the last two days. The pain was colicky in nature. Examination revealed fullness and tenderness in upper abdomen, Right para-median scar of laparotomy with increased

bowel sounds were noted. There was a history of abdominal surgery done 20 years back but the reason and procedure were unknown with no record available. Abdominal ultrasound gave the impression of intussusception of small gut. Endoscopic examination revealed a bosselated mass in the area of body of stomach with intact mucosa and peristalsis in the mass. The endoscope could not go beyond this point. CT scan of the abdomen revealed a whirlpool sign at the splenic flexure (Fig I).

The patient was resuscitated and an exploratory laparotomy was done under general anesthesia. The abdomen was opened through the midline incision and small gut obstruction was seen with afferent and efferent loops entering into the stomach wall. The loop of the jejunum was delivered via gentle manual traction and hot sponges compression. The reduction of the intussusception was done (Fig. II). There was posteriorly located gastrojejunostomy in the infracolic region and retrograde dependent area of stomach. About 25 cm of the jejunal loops were in the stomach wall. The gut was congested but viable. There was no leading point. Adhesiolysis of loops was done and stitched to mesentery of colon to avoid recurrence. Postoperative recovery was uneventful.

## DISCUSSION:

Jejunogastric intussusception as a complication may develop at any time in a patient who has undergone gastrojejunostomy.<sup>3</sup> Anatomically, jejuno gastric intussusceptions are classified into three types;

<sup>1</sup> Department of Surgery, Combined Military Hospital Multan

## Correspondence:

Dr. Hassan Shabbir <sup>1\*</sup>  
Department of Surgery,  
Combined Military Hospital  
Multan  
E mail: hassanshabbir07@hotmail.com

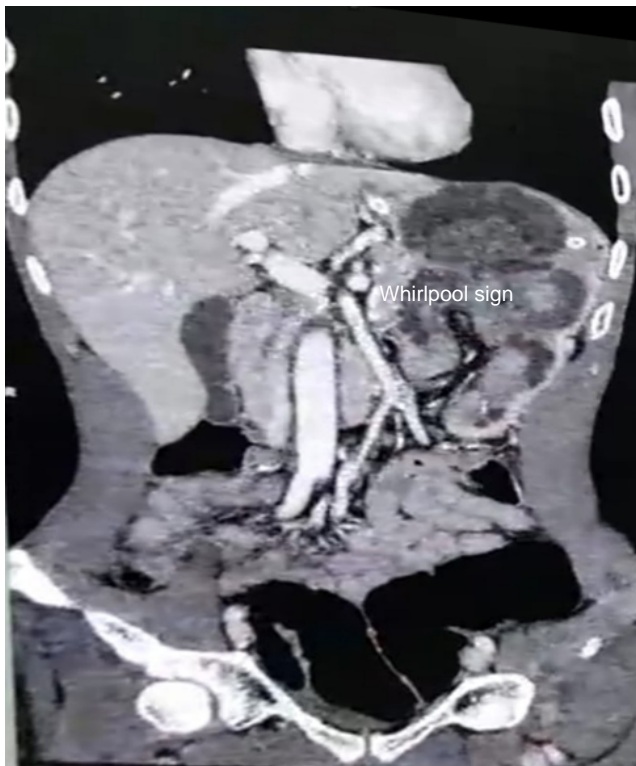

Fig. I: Whirlpool sign indicative of intussusception.

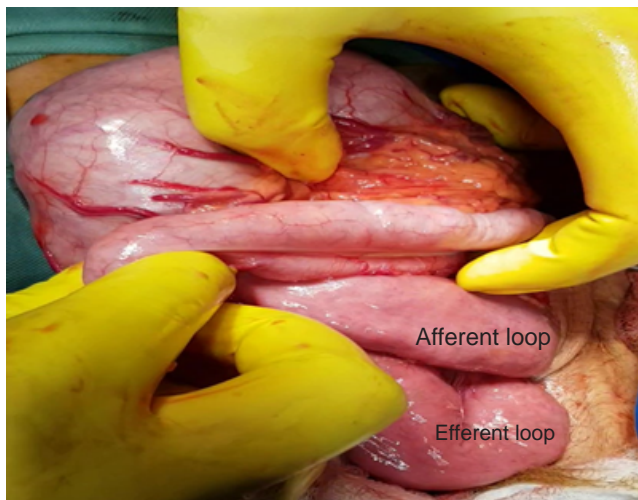


Fig II: Bowel loop being pulled out of stomach

Type I when afferent loop (anterograde) is involved (16%), Type II where efferent loop is involved (74%) and in Type III both loops are involved (10%). Based on this classification our patient falls in Type III. No clear mechanism is known. It is stated that hyperacidity, presence of a long efferent loop, presence of jejunal spasms together with abnormal motility in the bowel, increase pressure in the abdomen as well as reverse peristalsis are the leading pathophysiological factors that contribute to the condition.<sup>5</sup> Type II jejuno gastric intussusceptions are attributed to retrograde peristalsis.

The management of jejuno gastric intussusceptions include both endoscopic as well as surgical approach. The endoscopic method was not used in our patient because of large mass and diagnostic ambiguity. There are various surgical approaches to manage this condition depending upon the intraoperative findings.<sup>4</sup> This include gentle manual reduction, anastomotic site revision, efferent loop stitching to the nearby structures such as the mesentery. Same was used in our case. Prior to the surgical procedure viability of bowel must be assessed. Early diagnosis and treatment prevent complications and improve the quality of life of the patient.

**CONCLUSION:**

Intussusception may be considered in a patient who previously has undergone gastrojejunostomy as cause of intestinal obstruction even at long follow up.

**REFERENCES:**

1. Cipe G, Malya FU, Hasbahceci M, Ersoy EY, Karatepe O, Muslumanoglu M. Jejuno gastric intussusception: A rare complication of gastric surgery. *Case Rep Surg.* 2013; <https://doi.org/10.1155/2013/838360>
2. Lee SH, Kwon IG, Ryu SW, Sohn SS. Jejuno gastric intussusception: a rare complication of gastric cancer surgery. *Int. J Clin Exp Med.* 2014;7:4498-502.
3. Faruk I, Kabir SF, Alam SM, Hassan K. Retrograde jejuno gastric intussusception: a life-threatening complication after gastric bypass surgery. *J Bangladesh Coll Physicians Surg.* 2015;33:161-5.
4. Samson R, Munnamgi S, Abdul A. Antegrade jejuno jejunal intussusception inside a retrograde jejuno gastric intussusception (double intussusception) - A rare case report. *Int J Surg Case Rep.* 2017;39:264-6.
5. Yash V, Vaithianathan R. A rare case of jejuno gastric intussusception following gastric surgery. *Int J Surg Case Rep.* 2017;31:103-5.

Received for publication: 15-06-2019

Accepted after revision: 30-09-2019

Author's Contributions:

Farhan Ahmed Majeed: Conception and design of study, data analysis and manuscript review

Hassan Shabbir: Manuscript drafting & manuscript writing

Umar Bashir: Manuscript drafting

Ahmad Raza: literature review & proof reading of manuscript

Nabeela Farhan: literature review

Adil Qayyum: Data collection

Conflict of Interest:

The authors declare that they have no conflict of interest.

Source of Funding:

None

How to cite this article:

Majeed FA, Shabbir H, Bashir U, Raza A, Farhan N, Qayyum A. Intussusception after two decades of gastrojejunostomy with gastric outlet obstruction. *J Surg Pakistan*. 2019;24(3):158-60. Doi:10.21699/jsp.24.3.12.