

Squamous Papilloma At Vermillion Border of Lower Lip

Maryam Zafar,^{1*} Sufyan Ahmed¹

ABSTRACT

Squamous Papillomas are asymptomatic benign, slow growing, painless neoplasms that may arise from stratified squamous epithelium of skin or oral mucosa. They are believed to be induced by human papillomavirus 6 or 11. We present a case of a 63 year old male, with a squamous papilloma at vermillion border of lower lip extending to labial mucosa.

Key words Papilloma, Exophytic, Stratified squamous epithelium, Human papillomavirus.

INTRODUCTION:

Squamous papilloma mostly occur at posterior hard palate, ventral surface of tongue, soft palate, uvula, gingiva, lower lip and buccal mucosa. The mean age at which it can occur ranges between 30 to 60 years.¹ Squamous papilloma are innocuously benign in nature and are neither transmissible nor threatening. Human papilloma virus 6 or 11 play a role in its development.² They appear as small finger like projections, resulting in an exophytic lesion with a rough or pinkish cauliflower like surface. They might cause difficulty in speaking or chewing as well as of aesthetical concern.³ This article presents a rare occurrence of squamous papilloma at vermillion border of lip.

CASE REPORT:

A 63 year old male presented with gradually increasing mass on vermillion border of lower lip for the last three years. The growth started as a small solitary mass at anterior border of lower lip on left side and extended into intraoral labial mucosa. It was non tender and resembled rough lobulated whitish cauliflower like mass, measuring about 4.0 x 2.0 x 1.3 cm. It was firmly attached to the base of vermillion border (Fig. I). Cervical lymph nodes were not enlarged. Intraoral examination revealed an extension of growth about 2 cm, at lower left labial sulcus up to corner of mouth. Patient was a chronic

betel nut consumer for the last 7 years and presented with a poor oral hygiene and receded gingiva. CT scan of head and neck with contrast revealed involvement of orbicularis oris muscle, subcutaneous tissues and a bulge over left side of face. No bone erosion was noted.

After taking proper aseptic measures, punch biopsy was performed under local anesthesia at lower left labial sulcus and at vermillion border of left lower lip. The specimen was sent for histopathological examination. Histopathological report revealed squamous papilloma or verruca vulgaris. There was hyperkeratosis and parakeratosis with no dysplasia. Special stains for fungus PAS + D indicated presence of fungal infection. Adjacent tissue revealed mild inflammatory infiltrate. No evidence of malignancy or dysplasia was seen.

Patient was kept on antifungal drugs for a period of 14 days and advise was given oral hygiene. Re-biopsy under local anesthesia was performed and confirmed that fungal infection has subsided to a great extent. Surgical excision of the lesion at base with 1 mm of healthy margin, was carried. The excised lesion was sent for histopathological examination which confirmed it to be a squamous papilloma. Postoperative outcome remained uneventful. No recurrence was noted at follow up (Fig. II).

DISCUSSION:

Squamous papilloma is one of the most commonly occurring benign neoplasm that originates from squamous epithelium. They are usually asymptomatic, non tender exophytic masses.¹ There is no gender predilection. Human papilloma virus are commonly found in oral cavity and belong to non enveloped Papovavirus group, a DNA virus with a single molecule of double stranded DNA.⁴ Histologically,

¹ Department of Oral and Maxillofacial Surgery, Abbasi Shaheed Hospital Karachi Medical and Dental College Karachi

Correspondence:

Dr. Maryam Zafar^{1*}

Department of Oral and Maxillofacial Surgery
Abbasi Shaheed Hospital Karachi Medical and Dental
College Karachi

Email: drmaryam_zafar@hotmail.com

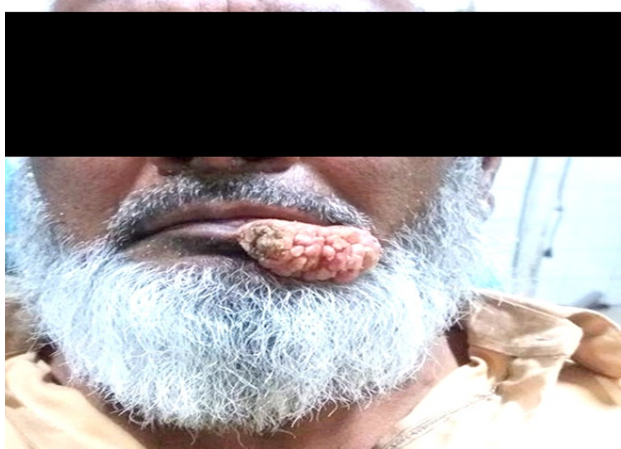


Fig I: Cauliflower like growth at the vermilion border of lower lip.

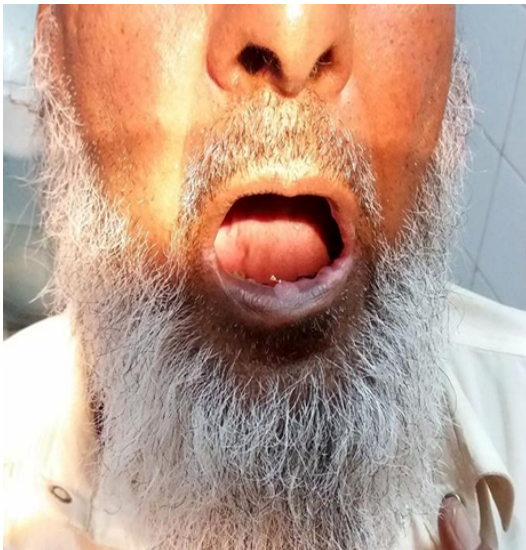

Fig. II: Patient at follow up following excision of the mass.

squamous papilloma occur as thin finger like projections with well-organized foci of connective tissue surrounded by benign squamous epithelium with abnormal mitotic figures, which rarely show any koilocytic or dysplastic changes.² Squamous papilloma usually occur as an isolated solitary lesion which is more common in adults or multiple recurring lesions involving laryngeal and tracheobronchial tree in children.¹ Malignant transformation is more common in multiple recurring lesions as compared to isolated solitary swelling.

Surgical excision of entire lesion by simple excision or using laser ablation, electrocautery, cryosurgery, is considered the most accepted treatment modality. About one mm healthy margin to the depth of submucosa should also be excised. There is about a 4% chance of recurrence of the lesion. In our

patient no recurrence was noted at follow up.

REFERENCES:

1. St Guily JL, Jacquard AC, Prétet JL, Haesebaert J, Beby-Defaux A, Clavel C, et al. Human papillomavirus genotype distribution in oropharynx and oral cavity cancer in France—The EDiTH VI study. *J Clin Virol.* 2011;51:100-4.
2. Anaya-Saavedra G, Flores-Moreno B, García-Carrancá A, Irigoyen-Camacho E, Guido-Jiménez M, Ramírez-Amador V. HPV oral lesions in HIV-infected patients: the impact of long-term HAART. *J Oral Pathol Med.* 2013;42:443-9.
3. Fatahzadeh M, Schlecht NF, Chen Z, Bottalico D, McKinney S, Ostolozza J, Dunne A, et al. Oral human papillomavirus detection in older adults who have human immunodeficiency virus infection. *Oral Surg Oral Med Oral Pathol Oral Radiol.* 2013;115:505-14.
4. Kristoffersen AK, Enersen M, Kverndokk E, Sunde PT, Landin M, Solheim T, et al. Human papillomavirus subtypes in oral lesions compared to healthy oral mucosa. *J Clin Virol.* 2012;53:364-6.

Received for publication: 03-04-2018

Accepted after revision: 30-06-2018

Author's Contributions:

Maryam Zafar: Case report writing and patient follow up.
Sufyan Ahmed: Guided and supervised.

Conflict of Interest:

The authors declare that they have no conflict of interest.

Source of Funding:

None

How to cite this article:

Zafar M, Ahmed S. Squamous papilloma at vermilion border of lower lip. *J Surg Pakistan.* 2018;23(2):81-82. Doi:10.21699/jsp.23.2.10.