

# Cervical Teratoma: A Management Challenge

Mishraz Shaikh,<sup>1\*</sup> Jamshed Akhtar<sup>1</sup>

## ABSTRACT

*Congenital cervical teratomas are rare germ cell tumors. Most of these are benign in nature but their management remains challenging due to grotesque size, posing life threatening airway compromise. When decision of surgical removal is made then anesthesia related issues need proper planning so as to ensure control of airway both during induction and surgery. We report two cases of cervical teratomas in whom total excision was performed.*

*Key words* Germ cell tumor, Cervical teratoma, Newborn.

## INTRODUCTION:

Teratomas are known to occur anywhere in the body, the commonest location being sacral region. Cervical presentation constitutes 1.6-9.3% of all pediatric teratomas, roughly equal to 1 per 40,000 births. They occur more frequently in females.<sup>1</sup> Cervical teratoma is an anomaly that has the potential for upper airway obstruction secondary to tracheal compression. Newborns usually present with upper airway obstruction. Early diagnosis and planned management are of paramount importance for the survival of these infants. We describe two cases of cervical teratomas with huge neck mass leading to upper airway obstruction.

## CASE - I:

A newborn male baby presented with a large cervical teratoma occupying whole of anterior neck with airway compromise (Fig-I). Computed tomography neck showed a large multiloculated, solid cum cystic lesion measuring 8.8 cm x 10 cm x 9 cms extending from angle of mandible up to the left supraclavicular fossa, across front of neck and onto right side (Fig-II). It was difficult endotracheal intubation for the anesthetist and videolaryngoscope was used to facilitate the procedure but it was not successful.

At surgery a large multilobulated solid / cystic mass was found displacing the vital neck structures but easily separable with diathermy dissection (Fig-III). During surgery one of the cysts got ruptured but spillage was minimal. Postoperatively ventilator support was not required. Biopsy report showed immature teratoma. Patient was managed in neonatology unit but remained in respiratory distress probably due to tracheomalacia. This patient expired on 6<sup>th</sup> postoperative day due to sepsis.

## CASE - II:

An 11-month-old girl was admitted with huge cystic swelling on right lateral side of neck extending up to anterior aspect. This mass was present at birth. Initial diagnosis in neonatal period was cystic hygroma because of cystic feel with positive transillumination test (Fig-IV). Patient received two doses of intralesional betamethasone resulting in solid

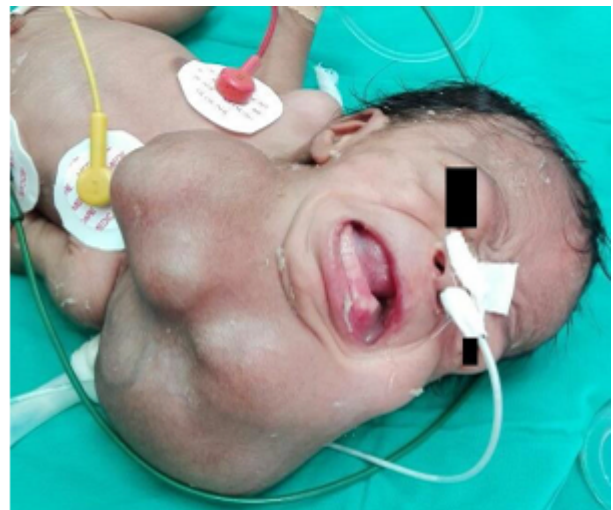

Fig I: Newborn with large neck mass

<sup>1</sup> Department of Pediatric Surgery, National Institute of Child Health, Jinnah Sindh Medical University, Karachi.

## Correspondence:

Dr. Mishraz Shaikh<sup>1\*</sup>  
 Department of Pediatric Surgery,  
 National Institute of Child Health,  
 Jinnah Sindh Medical University, Karachi  
 E mail: mishraz\_lumhs@hotmail.com

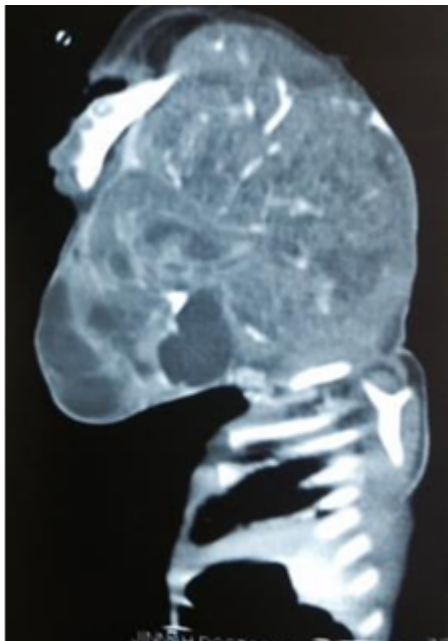


Fig II: CT-scan head and neck showing heterogeneous mass with calcification

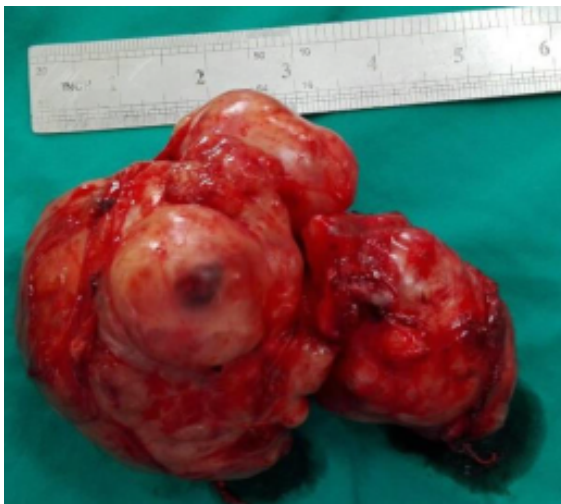

Fig III: Completely excised tumor

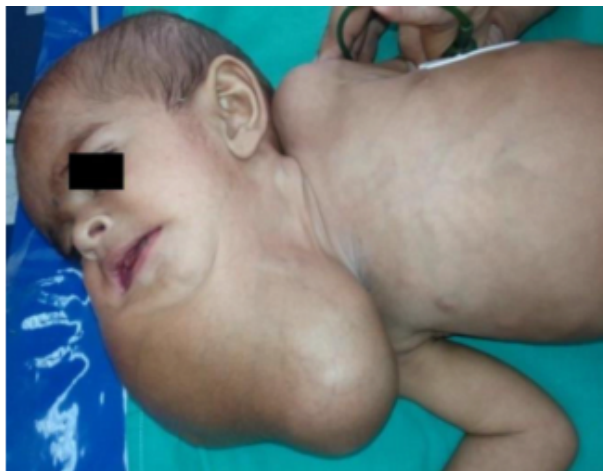

Fig IV: Infant with right lateral neck mass

consistency of mass. Patient had no breathing and swallowing difficulties. With time lesion persisted without any significant change in size. A decision of surgical removal was therefore made. Examination under anesthesia revealed some mobility of the mass and diagnosis of teratoma was made. Surgical excision was not difficult as mass pushed the surrounding structures outwards without invading them. Gross examination of the cut section of the mass showed multinodular cystic mass. Tumor markers (beta-HCG and alpha protein) sent after surgery, were within normal range. CT scan neck done earlier was reviewed in retrospect. It showed mass measuring 10cm x 8cm, consisting of mixed solid and cystic components with focal calcifications which were not taken into consideration earlier.

Postoperatively, postural torticollis persisted. Patient was discharged with advice to use cervical collar and neck exercise. Histopathology examination confirmed the diagnosis of mature teratoma.

#### DISCUSSION:

Over 90% of all the reported cases of teratomas are found in neonates. In most of the cases diagnosis is made on antenatal ultrasound, however in both the reported patients it was not done. The diagnosis of cervical teratomas may be difficult before surgery as cystic hygroma occur more frequently in this location. Preoperative evaluation should include CT scan to provide important information regarding extent of the mass and its relation to vital structures. At times calcification can be picked up thus helping in making diagnosis. This was missed in second patient as there was impression that IV contrast was also used during scan.

Clinically, cervical teratoma appears as a large mass with airway compromise. This is the most dangerous complication in tumors that are located in front of the neck.<sup>3</sup> Differential diagnosis also include neonatal goiter. Complete excision is the mainstay of the treatment. The procedure must not be delayed though lesions are mostly benign.

A good presurgical planning is important. An expert anesthetist is needed who can intubate such patients. Videolaryngoscope may aid endotracheal intubation. In first case it was not possible and plan for tracheostomy was made but ultimately with the use of stylet anesthetist was able to intubate. With complete surgical excision there are no chances of recurrence in benign lesions.<sup>3</sup> We hope to achieve the same long-term outcome though a regular follow-up is necessary.<sup>5</sup>

**CONCLUSIONS:**

Cervical teratoma should be considered in differential diagnosis of neck masses in neonates. Early diagnosis by antenatal ultrasound, airway management and multidisciplinary team approach are important steps in management of these patients.

Received for publication: 13-04-2017

Accepted after revision: 15-05-2017

**Author's Contributions:**

Mishraz Shaikh: Manuscript writing.

Jamshed Akhtar: Manuscript writing.

**REFERENCES:**

1. Uchiyama M, Iwafuchi M, Naitoh S, Matsuda Y, Naitoh M, Yagi M et al. A huge immature cervical teratoma in a newborn: report of a case. *Surg Today*. 1995;25:737-40.
2. Howell CG, Van Tassel P, El Gammal T. High resolution computed tomography in neonatal nasopharyngeal teratoma. *J Comp Assist Tomogr*. 1984;8:1179-81.
3. Bianchi B, Ferri A, Silini EM, Magnani C, Sesenna E. Congenital cervical teratoma: a case report *J Oral Maxillofac Surg*. 2010;68:667-70.
4. Batsakis JG1, el-Naggar AK, Luna MA. Teratomas of the head and neck with emphasis on malignancy *Ann Otol Rhinol Laryngol*. 1995;104:496-500.
5. Benouaiche L, Couly G, Michel B, Devauchelle B. Diagnosis and management of cervicofacial congenital teratomas: about 4 cases, literature review and restatement. *Ann Chir Plast Esthet*. 2007;52:114-23.
6. Shine NP, Sader C, Gollow I, Lannigan FJ. Congenital cervical teratomas: diagnostic, management and postoperative variability *Auris Nasus Larynx*. 2006;33:107-11.
7. Mohanty MK, Sahu P, Jaiswal AA, Singal R, Gupta S, Kohli G, et al, A huge immature cervical teratoma; antenatal diagnosis, and its management – an unusual entity. *J Clin Neonatol*. 2013;2:42-45.

**Conflict of Interest:**

The authors declare that they have no conflict of interest.

Source of Funding: None

**How to cite this article:**

Shaikh M, Akhtar J. Cervical Teratoma: A management challenge. *J Surg Pakistan*. 2017;22 (2):68-70. doi:<http://dx.doi.org/10.21699/jsp.22.2.9>.